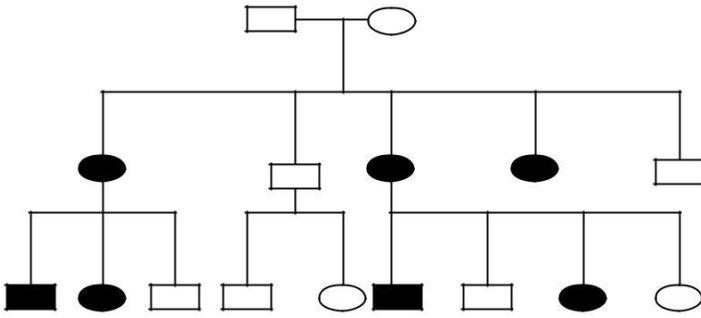


(AIIMS Paper: May-2004)

1. A forty four year old man presented with acute onset of low backache radiating to the right lower limb. Examination revealed SLRT<40 on the right side, weakness of extensor hallucis longus on the right side, sensory loss in the first web space of the right foot and brisk knee jerk. Which of the following is the most likely diagnose
 1. Prolonged intervertebral disc L4-5
 2. Spondylolysis L5-S1
 3. Lumbar canal stenosis
 4. Spondylolisthesis L4-5
2. A woman of forty-five, a known case of pemphigus vulgaris on a regular treatment with controlled primary disease presented with pain in the right hip and knee. Examination revealed no limb length discrepancy but the patient has tenderness in the Scarpa's triangle and limitation of adduction and internal rotation of the right hip joint as compared to the other side. The most probable diagnosis is:
 1. Stress fracture of neck of femur.
 2. Avascular necrosis of femoral head.
 3. Perthes' disease
 4. Transient synovitis of hip.
3. A 24-year-old male, known epileptic, presented following a seizure with pain in the right shoulder region. Examination revealed that the right upper limb adducted and internally rotated and the movements could not be performed. Which of the following is the most likely diagnosis?
 1. Posterior dislocation of shoulder
 2. Luxatio erecta
 3. Intrathoracic dislocation of shoulder
 4. Subglenoid dislocation of shoulder
4. A 30-year-old male underwent excision of the right radial head. Following surgery, the patient developed inability to extend the fingers and thumb of the right hand. He did not have any sensory deficit. Which one of the following is the most likely cause?
 1. Injury to posterior interosseous nerve.
 2. Intra-articular injury to common extensor origin
 3. Injury to anterior Interosseous nerve.
 4. High radial nerve palsy.
5. A ten-year-old boy presenting with a cubitus varus deformity and a history of trauma three months back on clinical examination, has the preserved three bony points relationship of the elbow. The most probable clinical diagnosis is:
 1. Old unreduced dislocation of elbow
 2. Non-union lateral condylar fracture of humerus.
 3. Malunited inter condylar fracture of humerus.
 4. Malunited supracondylar fracture of humerus.
6. All of the following cause a grey-white membrane on the tonsils, except:
 1. Infectious mononucleosis
 2. Ludwig's angina
 3. Streptococcal tonsillitis
 4. Diphtheria.
7. A 65-year-old smoker presents with hoarseness, haemoptysis and a hard painless lump in the left supraclavicular fossa. Which of the following is the most appropriate diagnostic step?
 1. Undertake an open biopsy of the neck lump
 2. Undertake a radical neck dissection
 3. Do fine needle aspiration cytology.
 4. Give a trial of Anti tuberculous therapy.
8. All of the following conditions are known to cause diabetes insipidus except:
 1. Multiple sclerosis
 2. Head injury
 3. Histiocytosis
 4. Viral encephalitis
9. A tracheostomised patient, with portex tracheostomy tube, in the ward, developed sudden complete blockage of the tube. Which of the following is best next step in the management/
 1. Immediate removal of the tracheostomy tube.
 2. Suction of tube with sodium bicarbonate.
 3. Suction of tube with saline.
 4. Jet ventilation.
10. All of the following surgical procedures are used for allergic Rhinitis, except:
 1. Radiofrequency ablation of the inferior turbinate.
 2. Laser ablation of the inferior turbinate.
 3. Submucosal placement of silastic in inferior turbinate.
 4. Inferior turbinectomy.

2004

11. Which of the following is the most likely inheritance pattern in the pedigree given below?



1. Autosomal dominant
 2. Mitochondrial
 3. Autosomal recessive
 4. X-linked dominant.
12. If both husband and wife are suffering with achondroplasia, what are their chances of having a normal child?
1. 0%
 2. 25%
 3. 50%
 4. 100%
13. A two-year-old boy has vitamin D resistant rickets. His investigations revealed serum calcium – 9 mg/dl, phosphate – 2.4 mg/dl, alkaline phosphatase 1041 IU, normal intact parathyroid hormone and bicarbonate 22 mEq/l. Which of the following is the most probable diagnosis?
1. Distal renal tubular acidosis.
 2. Hypophosphatemic rickets.
 3. Vitamin D dependent rickets.
 4. Hypoparathyroidism
14. The renal biopsy of a 6-year-old boy with recurrent gross hematuria shows IgA nephropathy. The urinary protein excretion is 130 mg/day. Which of the following is the most appropriate next step in the management?
1. Administer corticosteroids.
 2. Give azathioprine
 3. Start Cyclosporine
 4. Urinary bag sample
15. Which of the following is the most appropriate method for obtaining a urine specimen for culture in an 8-month-old girl?
1. Suprapubic aspiration
 2. Indwelling catheter sample
 3. Clean-catch void
 4. Urinary bag sample.

16. An 8 year-old-boy during a routine check up is found to have E.coli 1,00,000 cc/ml on a urine culture. The urine specimen was obtained by mid-stream clean-catch void. The child is asymptomatic. Which is the most appropriate next step in the management?

1. Treat as an acute episode of urinary tract infection
 2. No therapy
 3. Prophylactic antibiotics for 6 months
 4. Administer long-term urine alkalinizer.
17. In which of the following conditions, aniridia and hemihypertrophy are most likely present?
1. Neuroblastoma
 2. Wilms' tumour
 3. Non-Hodgkin's lymphoma
 4. Germ-cell tumor.
18. A 2-year-old child comes with discharge, seborrheic dermatitis, polyuria and hepatosplenomagaly. Which of the following is the most likely diagnosis?
1. Leukemia
 2. Lymphoma
 3. Langerhan's cell histiocytosis
 4. Germ cell tumour
19. All of the following drugs are contraindicated in patients with G-6-PD deficiency except:
1. Co-trimoxazole
 2. Furazolidone
 3. Nalidixic acid
 4. Ceftriaxone
20. Injection glucagons is effective for management persistent hypoglycemia in all, Except:
1. Large for date baby
 2. Galactosemia
 3. Infant of diabetic mother.
 4. Nesidioblastosis
21. The most appropriate management for maintaining patency of ductus arteriosus in a neonate is:
1. Prostaglandin E₁.
 2. Nitric oxide.
 3. Oxygen.
 4. Indomethacin
22. During surgery of hernia, the sac of a strangulated inguinal hernia should be opened at the:
1. Neck
 2. Body
 3. Fundus
 4. Deep ring
23. Raised serum amylase levels are used to diagnose:
1. Autoimmune disease
 2. Degenerative diseases
 3. Acute cholecystitis
 4. Acute pancreatitis

24. In the mitogen activated protein kinase pathway, the activation of Ras is counteracted by;
1. Protein kinase C.
 2. GTPase activating protein
 3. Phosphatidyl inositol
 4. Inositol triphosphate.
25. Wire loop lesions are often characteristic for the following class of lupus nephritis:
1. Mesangial proliferative glomerulonephritis (WHO class II)
 2. Focal proliferative glomerulonephritis (WHO class III)
 3. Diffuse proliferative glomerulonephritis (WHO class IV)
 4. Membranous glomerulonephritis (WHO class V)
26. Which one of the following is a cause for "restrictive" cardiomyopathy:
1. Alcohol
 2. Hemochromatosis
 3. Amyochromatosis
 4. Sarcoidosis
27. Which of the following lesions is associated with HIV infection?
1. Hairy leukoplakia
 2. Erythroplakia
 3. Oral lichen planus.
 4. Bullous pemphigoid
28. The most common site of a benign (peptic) gastric ulcer is:
1. Upper third of lesser curvature
 2. Greater curvature
 3. Pyloric antrum
 4. Lesser curvature near incisura angularis.
29. Which of the following would be the best morphological feature to distinguish ulcerative colitis from Crohn's disease:
1. Diffuse distributions of pseudopolyps.
 2. Mucosal edema
 3. Crypt abscesses.
 4. Lymphoid aggregates in the mucosa.
30. In Chronic Viral Hepatitis:
1. Hepatitis A virus infection is a common cause in children
 2. Morphological classification into Chronic Active Hepatitis and Chronic Persistent Hepatitis are important.
 3. Fatty change is pathognomonic of Hepatitis C Virus infection
 4. Grading refers to the extent of necrosis and inflammations
31. Mesangial deposits of monoclonal Kappa/Lambda light chains is indicative of:
1. Mesangioproliferative glomerulonephritis
 2. Focal and segmental glomerulosclerosis
 3. Kimmelsteil-Wilson lesions
 4. Amyloidosis
32. A 59-year-old male came with Hb 18.0g/dl on three occasions. The resident doctor wants to exclude Polycythemia Vera. Which of the following is the most relevant investigation/
1. Hematocrit
 2. Total leucocyte count
 3. Red cell mass
 4. Reticulocyte count
33. A 20-year-old female, asymptomatic, not requiring blood transfusion, presents with Hb 13.0g/dl. Her HbF levels are 95%, Hb A2 1.5%. Which of the following is the most likely diagnosis?
1. Hereditary persistence of fetal hemoglobin
 2. Beta homozygous thalassemia.
 3. Thalassemia intermedia
 4. Beta heterozygous thalassemia
34. In a patient with acute leukemia Immunophenotype pattern is CD 19+ve, CD 10+ve, CD33+ve, CD 13+ve. He may probably have:
1. Biphenotypic leukemia
 2. ALL
 3. AML-M2
 4. AML-MO
35. A patient with cirrhosis of liver has the following coagulation parameters, platelet count 200,000, Prothrombin time 25s/12s, Activated partial thromboplastin time 60s/35s, thrombin time 15s/15s. In this patient:
1. D-dimer will be normal
 2. Fibrinogen will be <100mg.
 3. ATIII will be high
 4. Protein C will be elevated.
36. The liver biopsy in acute hepatitis due to hepatitis B virus is likely to show all of the following except:
1. Ballooning change of hepatocytes
 2. Ground glass hepatocytes
 3. Focal or spotty necrosis
 4. Acidophil bodies
37. Which of the following is not a prodrug:
1. Enalapril
 2. Oxcarbazepine
 3. Chloralhydrate
 4. Diazepam

38. Which of the following antimalarial is a schizonticide;
 acting schizonticide;
1. Artemether
 2. Mefloquine
 3. Pyrimethamine
 4. Quinine
39. In which of the following condition Thalidomide may be used?
1. Myocardial infarction
 2. Erythema nodosum leprosum
 3. Wernicke's Encephalopathy
 4. Epilepsy
40. Aldosterone antagonists are not useful in the treatment of:
1. Hypertension
 2. Congestive heart failure
 3. Gynecomastia
 4. Hirsutism
41. The following statements are true for therapy with lithium, except:
1. It is used in bipolar disorder
 2. Thiazides are useful in treating lithium induced diabetes insipidus
 3. Regular measurements of blood concentration of lithium is necessary
 4. Na⁺ is a specific antidote for lithium intoxication
42. Which one of the following is not used in glaucoma
1. Timolol
 2. Physostigmine
 3. Donepezil
 4. Dipivefrine
43. Which of the following is fourth generation cephalosporin
1. Ceftriaxone
 2. Cefaclor
 3. Cefepime
 4. Cefuroxime
44. Which of the following drug causes Pseudotumor cerebri
1. Sparfloxacin
 2. Tetracycline
 3. Gentamicin
 4. Clofazimine
45. Which of the following condition is caused by Amphotericin B
1. Hypokalemia
 2. Hyperkalemia
 3. Hypermagnesemia
 4. Hyponatremia
46. In renal disease albumin is first to appear in urine because
1. Of its high concentration in plasma
 2. Has molecular weight slightly greater than the molecules normally getting filtered
 3. High albumin – globulin ratio
 4. Tubular epithelial cells are sensitive to albumin
47. Huntigton's disease is due to the loss of
1. Nigrostrial dopaminergic neurons
 2. Intrastratial cholinergic neurons
 3. Intrastratial GABA ergic neurons
 4. Intrastratial cholinergic and GABA ergic neurons
48. Which one of the following clearly states the role of cerebellum in motor performance
1. Planning and programming of movement
 2. Convert abstract thought into voluntary action
 3. Initiation of skilled voluntary action
 4. Smoothers and coordinates ongoing movements
49. Lesion in which of the following structure leads to Kluver – Bucy syndrome
1. Amygdala
 2. Hippocampus
 3. Hypothalamus
 4. Temporal lobe
50. Which of the following phrase adequately describes Pacinian corpuscles
1. A type of pain receptors
 2. Slowly adapting touch receptors
 3. Rapidly adapting touch receptors
 4. Located in the joints
51. Ovulation is associated with sudden rise in
1. Prolactin
 2. Testosterone
 3. LH
 4. Oxytocin
52. The normal adult human electroencephalogram (EEG)
1. Will not show high frequency waves during stage 3 sleep
 2. Shows alpha rhythm when a person is awake but inattentive
 3. Has lower frequency waves during mental activity
 4. Is predominated by large amplitude waves during REM sleep
53. The neuromuscular blocking action of curare is brought about by
1. Blocking acetylcholine synthesis
 2. Preventing the release of acetylcholine
 3. Causing persistent depolarization
 4. Competitive inhibition

54. The afferent nerve fibres which are most sensitive to local anaesthetic belong to Group
1. A
 2. B
 3. C
 4. D
55. Lower oesophageal sphincter
1. Has no tonic activity
 2. Has a tone which is provided by the sympathetic system
 3. Relaxes on increasing abdominal pressure
 4. Relaxes ahead of the peristaltic wave
56. Which of the following is the most common endocrine tumour of pancreas
1. Insulinoma
 2. Gastrinoma
 3. VIPoma
 4. Glucagonoma
57. Drinking can be induced by
1. Electrical stimulation of the posterior hypothalamus
 2. Osmotic stimulation of supraoptic nucleus
 3. Lesions in the paraventricular nucleus
 4. Neuronal lesion of the preoptic nucleus
58. Meiosis occurs in human males in
1. Epididymis
 2. Seminiferous tubules
 3. Vas deferens
 4. Seminal vesicles
59. When information memorized afterwards is interfered by the information learnt earlier, it is called
1. Retroactive inhibition
 2. Proactive inhibition
 3. Simple inhibition
 4. Inhibition
60. A 23-year-old engineering student is brought by his family to the hospital with history of gradual onset of suspiciousness, muttering and smiling without clear reason, decreased socialization, volent outbursts, and lack of interest in studies for 8 months. Mental status examination revealed a blunt affect, thought broadcast, a relatively preserved cognition, impaired judgment and insight. He is most likely to be suffering from
1. Delusional disorder
 2. Depression
 3. Schizophrenia
 4. Anxiety Disorder
61. A 34-year-old housewife reports a three month history of feeling low, lack of interest in activities, lethargy, multiple body – aches, ideas of worthlessness, decreased appetite and disturbed sleep with early morning awakening. She is likely to benefit from
1. Anti – psychotics
 2. Anti – depressants
 3. Anxiolytics
 4. Hypno – sedatives
62. A 31-year-old male, with mood disorder, on 30 mg of haloperidol and 1000 mg of lithium, is brought to the hospital emergency room with history of acute onset of fever, excessive sweating, confusion, rigidity of limbs and decreased communication for a day. Examination reveals tachycardia and labile blood pressure and investigations reveal increased CPK enzyme levels and leucocytosis. He is likely to have developed
1. Lithium toxicity
 2. Tardive dyskinesia
 3. Neuroleptic malignant syndrome
 4. Hypertensive encephalopathy
63. A 19-year-old body suffering from chronic schizophrenia is put on haloperidol in the dose of 20 mg/day. A week after the initiation of medication the patient shows be restlessness, fidgety, irritability and cannot sit still at one place. The most appropriate treatment strategy is
1. Increase in the dose of haloperidol
 2. Addition of anticholinergic drug
 3. Addition of betablocker
 4. Adding another antipsychotic drug
64. A 42-year-old male with a past history of a manic episode presents with an illness of a 1 month duration characterized by depressed mood, anhedonia and profound psychomotor retardation. The most appropriate management strategy is prescribing a combination of
1. Antipsychotics and antidepressants
 2. Antidepressants and mood stabilizers
 3. Antipsychotics and mood stabilizers
 4. Antidepressants and benzodiazepines
65. A 25-year-old man presented with fever and cough for two months. CT chest showed bilateral upper lobe fibrosis and mediastinal enlarged necrotic nodes with peripheral rim enhancement. What is the most likely diagnosis
1. Sarcoidosis
 2. Tuberculosis
 3. Lymphoma
 4. Silicosis

2004

66. For the evaluation of blunt abdominal trauma which of the following imaging modalities is ideal
1. Ultrasonography
 2. Computed Tomography
 3. Nuclear Scintigraphy
 4. Magnetic Resonance Imaging
67. Which one of the following statements is wrong regarding adult polycystic kidney disease
1. Kidneys are enlarged in size
 2. The presentation is unilateral
 3. Intracranial aneurysms may be associated
 4. Typically manifests in the 3rd decade
68. Following are common features of malignant gastric ulcer on barium meal except
1. Location on the greater curvature
 2. Carman's meniscus sign
 3. Radiating folds which do not reach the edge of the ulcer
 4. Lesser curvature ulcer with a nodular rim
69. Cock's peculiar tumor is
1. An infected sebaceous cyst
 2. A malignant tumor of the scalp
 3. A metastatic lesion of the scalp
 4. An indicator of underlying osteomyelitis
70. Angiographically, the typical "beaded" or "pile or plates" appearance involving the internal carotid artery is observed in
1. Takayasu's Disease
 2. Non-specific aorto-arteritis
 3. Fibromuscular dysplasia
 4. Rendu-Osler-Weber Disease
71. A 43-year-old lady presents with a 5 cm lump in right breast with a 3 cm node in the supraclavicular fossa. Which of the following TNM stage she belongs to as per the latest AJCC staging system
1. T2N0M1
 2. T1N0M1
 3. T2N3M0
 4. T2N2M0
72. What dose of radiation therapy is recommended for pain relief in bone metastases
1. 8 Gy in one fraction
 2. 20 Gy in 5 fraction
 3. 30 Gy in 10 fraction
 4. Above 70 Gy
73. Mean hemoglobin of a sample of 100 pregnant women was found to be 10 mg% with a standard deviation of 1.0 mg%. The standard error of the estimate would be
1. 0.01
 2. 0.1
 3. 1.0
 4. 10.0
74. Which of the following tumors have an increased elevation of placental alkaline phosphates in the serum as well as a positive immunohistochemical staining for placental alkaline phosphatase
1. Seminoma
 2. Hepatoblastoma
 3. Hepatocellular carcinoma
 4. Peripheral neuroectodermal tumor
75. A patient with cancer received extreme degree of radiation toxicity. Further history revealed that the dose adjustment of a particular drug was missed during the course of radiotherapy. Which one of the following drugs required a dose adjustment in that patient during radiotherapy in order to prevent radiation toxicity
1. Vincristine
 2. Dactinomycin
 3. Cyclophosphamide
 4. 6-Mercaptopurine
76. On performing refraction using a plane mirror on a patient who has a refractive error of -3 diopter sphere with -2 diopter cylinder at 90° from a distance of 1 meter under no cycloplegia, the reflex would be seen to move
1. With the movement in the horizontal axis and against the movement in the vertical axis
 2. With the movement in both the axes
 3. Against the movement in both axes
 4. With the movement in the verticals and against the movement in horizontal axis
77. A 25-year-old male gives a history of redness, pain and mild diminution of vision in one eye for past 3 days. There is also a history of low backache for the past one year. On examination there is circumferential congestion, cornea is clear apart from a few fine keratic precipitates on the corneal endothelium, there are 2+ cells in the anterior chamber and the intraocular pressure is within normal limits. The patient is most likely suffering from
1. Acute attack of angle closure glaucoma
 2. HLA B-27 related anterior uveitis
 3. JRA associated uveitis
 4. Herpetic keratitis
78. A soft contact lens user presents to you with pain, watering, photophobia and a white spot in the center of the cornea. What will be your initial management
1. Start frequent antibiotic eye drops after discontinuing the contact lens
 2. Pad and bandage the eye for 12 hrs
 3. Frequent instillation of artificial tears
 4. Topical non-steroidal anti-inflammatory drugs (NSAID)

2004

79. A 3 year old child presents with a right convergent squint of 6 months duration .what is the appropriate management?
1. Immediate surgical correction followed by amblyopia therapy
 2. Proper refractive correction, amblyopia therapy followed by surgical correction
 3. Prescribe spectacles and defer surgery until the child is 5 year old
 4. Botulinum toxin injection followed by occlusion therapy
80. A young man aged 30 years, presents with difficulty in vision in the left eye for the last 10 days. He is immunocompetent, a farmer by occupation, comes from a rural community and gives history of trauma to his left eye with vegetative matter 10 – 15 days back. On examination, there is an ulcerative lesion in the cornea, whose base has raised soft creamy infiltrate. There are a few satellite lesions also. The most probable aetiological agent is
1. Acanthamoeba
 2. Corynebacterium diphtheriae
 3. Fusarium
 4. Streptococcus pneumoniae
81. The right lobe of the liver consists which of the following segments
1. V, VI, VII and VIII
 2. IV, V, VI, VII and VIII
 3. I, V, VI, VII and VIII
 4. I, IV, V, VI, VII and VIII
82. Which of the following statements about the Holmium: YAG laser is incorrect
1. It has wavelength of 2100 nm
 2. Its use for uric acid stones has caused deaths due to generation of cyanide
 3. It is effective against the hardest urinary stones
 4. It can even cut the wires of stone urinary
83. Congenital hypertrophic pyloric stenosis usually presents
1. Within 2 days after birth
 2. Around 1 week after birth
 3. Around 2 weeks after birth
 4. Around 2 months after birth
84. Which of the following liver tumour has a propensity to invade the portal or hepatic vein
1. Cavernous haemangioma
 2. Hepatocellular carcinoma
 3. Focal Nodular hyperplasia
 4. Hepatic adenoma
85. ‘Weak Giants’ are produced by
1. Thyroid adenomas
 2. Thyroid carcinomas
 3. Para thyroid adenomas
 4. Pituitary adenomas
86. Wedged hepatic venous pressure represents the pressure in the
1. Main portal vein
 2. Main hepatic vein
 3. Sinusoids
 4. Central vein radicles
87. Which of the following usually products osteoblastic secondaries
1. Carcinoma lung
 2. Carcinoma breast
 3. Carcinoma urinary bladder
 4. Carcinoma prostate
88. Carcinoid syndrome produces valvular disease primarily of the
1. Venous valves
 2. Tricuspid valve
 3. Mitral valve
 4. Aortic valve
89. Carcinoid tumor is most common in
1. Esophagus
 2. Stomach
 3. Jejunum
 4. Appendix
90. The treatment of choice for a mucocele of gallbladder is
1. Aspiration of mucous
 2. Cholecystectomy
 3. Cholecystostomy
 4. Antibiotics and observation
91. For every 100, 000 population, the highest prevalence of blindness in the world is seen in
1. Sub – Saharan Africa
 2. South Asia
 3. Eastern Europe
 4. Latin America
92. Vesicoureteric reflux is more common in
1. New born females
 2. Older girls
 3. Older boys
 4. Only during pregnancy
93. Most common cause of subarachnoid hemorrhage is
1. Hypertension
 2. Aneurysm
 3. Arterio – venous malformation
 4. Bleeding disorders
94. The investigation of choice for imaging of urinary tract tuberculosis is
1. Plain X – ray
 2. Intravenous urography
 3. Ultrasound
 4. Computed tomography

2004

95. Bag and mask ventilation is contraindicated in
1. Cleft lip
 2. Meconium Aspiration
 3. Diaphragmatic hernia
 4. Multicentric Bronchogenic Cyst
96. Subdural hematoma most commonly results from
1. Rupture of intracranial aneurysm
 2. Rupture of cerebral AVM
 3. Injury to cortical bridging veins
 4. Haemophilia
97. Virchow's triad includes all of the following except
1. Venous stasis
 2. Injury to veins
 3. Blood Hypercoagulability
 4. Venous thrombosis
98. Following drugs are immunosuppressive drug except
1. Cyclosporin
 2. Cefaclor
 3. Azathioprine
 4. Steroids
99. The most common cause of superficial thrombophlebitis is
1. Trauma
 2. Infection
 3. Varicostities
 4. Intravenous infusion
100. "Sunary appearance" on x-rays is suggestive of
1. A chondrosarcoma
 2. A metastatic tumor in the bone
 3. An osteogenic sarcoma
 4. An Ewing's sarcoma
101. Which of the following local anaesthetics is most likely to produce an allergic reaction
1. Prilocaine
 2. Ropivacaine
 3. Etidocaine
 4. Benzocaine
102. All of the following drugs can induce methaemoglobinaemia, except
1. Nitroglycerine
 2. Procaine
 3. Prilocaine
 4. Phenytoin
103. A six-year-old child is posted for elective urology surgery under general anesthesia. He refuses to allow the anaesthesiologist an I.V. access. The best inhalational agent of choice for induction of anaesthesia is
1. Sevoflurane
 2. Methoxyflurane
 3. Desflurane
 4. Isoflurane
104. A seventy-year-old patient is posted for a surgery which is likely to last 4-6 hours. The best inhalational agent of choice for maintenance of anaesthesia in such a case is
1. Methoxyflurane
 2. Ether
 3. Trichlorethylene
 4. Desflurane
105. A 30-year-old lady is to undergo surgery under intravenous regional anesthesia for her left 'trigger finger'. Which one of the following should not be used for this patient
1. Lignocaine
 2. Bupivacaine
 3. Prilocaine
 4. Lignocaine + Ketorolac
106. A 21-year-old lady with a history of hypersensitivity to neostigmine is posted for an elective caesarean section under general anesthesia. The best muscle relaxant of choice in this patient should be
1. Pancuronium
 2. Atracurium
 3. Rocuronium
 4. Vecuronium
107. What would be the first line of treatment if a patient develops ventricular fibrillation after
108. After contrast media injection in the Radiology department, a patient develops severe hypotension, bronchospasm and cyanosis. Which one of the following drugs should be used for treatment
1. Atropine
 2. Aminophylline
 3. Dopamine
 4. Adrenaline
109. Which is the enzyme inhibited by aminophylline
1. Monoamine oxidase
 2. Alcohol dehydrogenase
 3. Cytochrome p-450
 4. Phosphodiesterase
110. The pressure volume curve is shifted to the left in
1. Mitral regurgitation
 2. Aortic regurgitation
 3. Mitral stenosis
 4. Aortic stenosis

2004

111. A young boy who was driving motorcycle at a high speed collided with a tree & was thrown on his right shoulder. Though there was no fracture, his right arm was medially rotated and forearm pronated. The following facts concerning this patient are correct, except
1. The injury was at Erb's point
 2. A lesion of C5 and C6 was present
 3. The median and ulnar nerves were affected
 4. Supraspinatus, infraspinatus, subclavius & biceps brachii were paralysed
112. In a vehicular accident, the musculocutaneous nerve was completely severed, but still the person was able to weakly flex the elbow joint. All of the following muscles are responsible for this flexion, except
1. Brachioradialis
 2. Flexor carpi radialis
 3. Ulnar head of pronator teres
 4. Flexor carpi ulnaris
113. A patient presented with normal eyesight and absence of direct and consensual light reflexes. Which of the following cranial nerves is suspected to be lesioned
1. Oculomotor
 2. Trochlear
 3. Optic
 4. Abducent
114. A baby girl with ambiguous genitalia is found to have 21-hydroxylase deficiency of the salt – wasting type. Which of the following karyotypes would you expect to find
1. 46, XX
 2. 46, XY
 3. 47, XXY
 4. 47, XYY
115. A man is rushed to casualty, nearly dying after a massive blood loss in an accident. There is not much time to match blood groups, so the physician decides to order for one of the following blood groups. Which one of the following blood groups should the physician decide
1. O negative
 2. O positive
 3. AB positive
 4. AB negative
116. The intrafusal fibres of the striated skeletal muscles are innervated by one of the following type of motor neurons. Choose the correct answers
1. Alpha
 2. Beta
 3. Gamma
 4. Delta
117. Misexpression of which of the following homeobox genes alters the position of the forelimbs during development
1. HOXA7
 2. HOXB8
 3. HOXC9
 4. HOXD10
118. Which of the following nuclei belongs to the general visceral efferent column
1. Facial nerve nucleus
 2. Trigeminal motor nucleus
 3. Dorsal nucleus of vagus
 4. Nucleus ambiguus
119. Dislocation of the vertebrae is uncommon in thoracic region because in this region
1. The articular processes are interlocked
 2. The vertebral body is long
 3. Anterior longitudinal ligament is strong
 4. Spinous process is long and pointed
120. Joint between epiphysis and diaphysis of a long bone is a type of
1. Plane synovial joint
 2. Fibrous joint
 3. Symphysis
 4. Spondylosis
121. A 30-years-old male patient presents with complains of weakness in right upper and both lower limbs for last 4 months. He developed digital infarcts involving 2nd and 3rd fingers on right side and 5th finger on left side. On examination, BP was 160/40 mm Hg, all peripheral pulses were palpable and there was asymmetrical neuropathy. Investigations showed a Hb – 12 gm, TLC – 12000 Cu mm, Platelets 4,30,000 and ESR – 49 mm. Urine examination showed proteinuria and RBC – 10 – 15/hpf with no casts. What is the most likely diagnosis
1. Polyarteritis nodosa
 2. Systemic lupus erythematosus
 3. Wegner's granulomatosis
 4. Mixed cryoglobulemia
122. All of the following statements about LDL are true except
1. It delivers cholesterol to cells
 2. It contains only one Apoprotein
 3. It is a marker for cardiovascular disease
 4. It contains Apo – B4
123. The protection against small pox by previous infection with cow pox represents
1. Antigenic cross – reactivity
 2. Antigenic specificity
 3. Passive Immunity
 4. Innate Immunity

2004

124. Which of the following class specific antigenic determinants of an immunoglobulin is associated with
1. L. Chain
 2. H. Chain
 3. J. Chain
 4. Variable region
125. The inhibitory neurotransmitter in CNS neurons is
1. Glutamate
 2. Aspartate
 3. Gamma – amino butyric acid
 4. Taurine
126. The most important source of reducing equivalents for fatty acid synthesis in the liver is
1. Glycolysis
 2. TCA cycle
 3. Uronic acid pathway
 4. HMP pathway
127. Insulin increases the activities of all of the following enzymes, except
1. Glucokinase
 2. Pyruvate carboxylase
 3. Glycogen synthase
 4. Acetyl – CoA carboxylase
128. Which of the following combinations of biologically active molecules does vitamin A consists of
1. Retinol, retinal and retinoic acid
 2. Retinol, retinal and tetrahydrofolate
 3. Retinol, conjugase and retinoic acid
 4. PABA, retinal and retinaldehyde
129. The primary structure of a protein refers to the
1. Linear number and order of the amino acids present
 2. Regular conformational forms of a protein
 3. Complete three – dimensional structure of the polypeptide units of a given protein
 4. Subunit structure of the protein
130. Excessive ultraviolet (UV) radiation is harmful to life. The damage caused to the biological systems by ultraviolet radiation is by
1. Inhibition of DNA synthesis
 2. Formation of thymidine dimers
 3. Ionization
 4. DNA fragmentation
131. Biological role of metallothioneins is to sequester harmful metal ions. These bind
1. Cd^{++} , Cu^{++} & Zn^{++}
 2. Al^{+++} , Hg^{++} & NH_4^+
 3. Pt^{++} , As^{+++} & PO_4^-
 4. Fe^{+++} , Na^+ & K^+
132. Which one of the following is not true for an α -helix
1. It is one of the most important secondary structure
 2. It has a net dipole moment
 3. All hydrogen bonds are aligned in the same direction
 4. Long stretches of left handed α -helices occur in proteins
133. Which one of the following infestations leads to malabsorption
1. Giardia lamblia
 2. Ascaris lumbricoides
 3. Necator Americana
 4. Ancylostoma duodenale
134. All of the following statements about plague are wrong, except
1. Domestic rate is the main reservoir
 2. Bubonic is the most common variety
 3. The causative bacillus can survive up to 10 years in the soil of burrows
 4. The incubation period for pneumonic plague is one to two weeks
135. National Health Policy of India – 2002 includes all the following includes all the following as goals, except
1. Eradicate Polio and yaws by year 2005
 2. Achieve zero level transmission of HIV/AIDS by year 2010
 3. Eliminate Kala – Azar by year 2005
 4. Eliminate Lymphatic Filariasis by year 2015
136. The incubation period for yellow fever is
1. 3 to 6 days
 2. 1 to 2 weeks
 3. 3 – 4 weeks
 4. 8 – 10 weeks
137. Which of the following is the mode of transmission of Q fever
1. Bite of infected louse
 2. Bite of infected tick
 3. Inhalation of aerosol
 4. Bite of infected mite
138. The following are characteristic features of staphylococcal food poisoning, except
1. Optimum temperature for toxin formation is 37 deg. C
 2. Intradietic toxins are responsible for intestinal symptoms
 3. Toxins can be destroyed by boiling for 30 minutes
 4. Incubation period is 1-6 hours

2004

139. Which of the following is the best indicator of severity of a short duration acute disease
1. Cause specific death rate
 2. 5 – year survival
 3. Case – fatality rate
 4. Standardized mortality ratio
140. All of the following are risk factors for carcinoma gall bladder, except
1. Typhoid carriers
 2. Adenomatous gall bladder polyps
 3. Choledochal cysts
 4. Oral contraceptives
141. Which of the following is the most common cause of maternal mortality in India
1. Hemorrhage
 2. Anemia
 3. Abortion
 4. Sepsis
142. Which of the following is the nodal ministry for Integrated Child Development Services (ICDS) Programme Centers
1. Ministry for Human Resource Development
 2. Ministry for Rural Development
 3. Ministry for Health and Family Welfare
 4. Social Justice
143. The systemic distortion of retrospective studies that can be eliminated by a prospective design is
1. Confounding
 2. Effect modification
 3. Recall bias
144. If we reject Null Hypothesis, when actually it is true, it is known as
1. Type 1 error
 2. Type 2 error
 3. Power
 4. Specificity
145. Hepatitis C virus is a
1. Toga Virus
 2. Flavi Virus
 3. Filo Virus
 4. Retro virus
146. If a new effective treatment is initiated and all other factors remain the same; which of the following is most likely to happen
1. Incidence will not change
 2. Prevalence will not change
 3. Neither incidence nor prevalence will change
 4. Incidence and prevalence both will change
147. Troponin-T is a marker of:
1. Renal diseases
 2. Muscular dystrophy
 3. Cirrhosis of liver
 4. Myocardial infarction
148. The gold standard for the diagnosis of osteoporosis is:
1. Dual energy X-ray absorptimetry
 2. Single energy X-ray absorptimetry
 3. Ultrasonography
 4. Quantitative computed tomography
149. Which one of the following relationships shown between different parameters of a performance of a test is correct
1. Sensitivity = 1 – specificity
 2. Positive Predictive Value = 1 – negative predictive value
 3. Sensitivity is inversely proportional to specificity
 4. Sensitivity = 1 – Positive predictive value
150. A 25-year-old female has been diagnosed to be suffering from tuberculosis categorized as category II (sputum +ve relapse). The treatment regimen recommended under DOTS is
1. 2 (HRZE)₃ + 5 (HR)₃
 2. 2 (HRSZE)₃ + (HRZE)₃ + 5 (HR)₃
 3. 3 (HRZE)₃ + 2 (HRE)₃ + 4 (HR)₃
 4. 3 (HRSZE)₃ + 1 (HRZE)₃ + 6 (HRE)₃
151. Which sampling method is used in assessing immunization status of children under an immunization program
1. Quota sampling
 2. Multistage sampling
 3. Stratified random sampling
 4. Cluster sampling
152. All the following statements are true about break point chlorination, except
1. Free chlorine is released in water after break point chlorination
 2. Chlorine demand is the amount needed to kill bacteria, oxidize organic matter and neutralize ammonia
 3. 1 ppm free chlorine should be present in water after break point has reached
 4. Contact period of 1 hour is necessary
153. A 9-year-old boy has multiple itchy erythematous wheals all over the body for 2 days. There is no respiratory difficulty. Which is the best treatment
1. Anthelmintics
 2. Systemic corticosteroids
 3. Antihistamines
 4. Adrenaline

154. A 23-year-old college student has asymptomatic and hyperpigmented macules on both palms for three weeks. The most appropriate diagnostic test is

1. Venereal Diseases Research Laboratory (VDRL) test
2. Skin biopsy
3. Serum cortisol levels
4. Assay for arsenic in skin, hair and nails

155. A forty-two-year-old engineer developed redness of the glans and radial fissuring of the prepuce 2 weeks ago. A potassium hydroxide preparation of scrapings from the glans showed pseudohyphae and buds. Which one of the following systemic illness should be screened for

1. Pulmonary tuberculosis
2. Diabetes mellitus
3. Systemic candidiasis
4. Chronic renal failure

156. A 27-year-old patient was diagnosed to have borderline leprosy and started on multibacillary multi-drug therapy. Six weeks later, he developed pain in the nerves and redness and swelling of the skin lesions. The management of his illness should include all of the following except

1. Stop anti-leprosy drugs
2. Systemic corticosteroids
3. Rest to the limbs affected
4. Analgesics

157. Rakesh, a 7-year-old boy had itchy, excoriated papules on the forehead and the exposed parts of the arms and legs for 3 years. The disease was most severe in the rainy season and improved completely in winter. The most likely diagnosis is

1. Insect bite hypersensitivity
2. Scabies
3. Urticaria
4. Atopic dermatitis

158. A 23-year-old male had unprotected sexual intercourse with a commercial sex worker. Two weeks later, he developed a painless, indurated ulcer on the glans which exuded clear serum on pressure. Inguinal lymph nodes in both groins were enlarged and not tender. The most appropriate diagnostic test is

1. Gram's stain of ulcer discharge
2. Darkfield microscopy of ulcer discharge
3. Giemsa stain of lymph node aspirate
4. ELISA for HIV infection

159. A three-month-old male infant developed otitis media for which he was given a course of co-trimoxazole. A few days later he developed extensive peeling of the skin; there were no

mucosal lesions and the baby was not toxic. The most likely diagnosis is

1. Toxic epidermal necrolysis
2. Staphylococcal scalded skin syndrome
3. Stevens Johnson syndrome
4. Infantile pemphigus

160. A 55-year-old male, with uncontrolled diabetes mellitus and hypertension, developed severe air-bone contact dermatitis. The most appropriate drug for his treatment would be

1. Systemic corticosteroids
2. Thalidomide
3. Azathioprine
4. Cyclosporine

161. In fresh water drowning the death occurs within 4-5 minutes of submersion due to ventricular fibrillation. Which of the following reasons is responsible for his

1. Total asphyxia is produced due to fresh water
2. Laryngospasm causing vagal inhibition
3. Haemoconcentration of blood caused by the osmotic pressure effect
4. Haemodilution, overloading of heart and haemolysis resulting in release of potassium.

162. A 25-year-old female was found in a room with 100% burns on her body. The tongue was protruding out, body was in pugilistic attitude with heat ruptures, peeling of skin, heat haematoma and heat fracture of skull. Carboxy haemoglobin was 25% and soot particles were present in trachea. Which of the combinations of two findings will establish that the burns were antemortem in nature

1. Heat Haematoma & heat ruptures
2. Heat fracture of skull and peeling of skin
3. Heat haematoma and pugilistic attitude
4. Carboxy haemoglobin (25%) and soot particles in trachea

163. The phenomenon of suspended animation may be seen in

1. Throttling
2. Drowning
3. Strangulation
4. Brain hemorrhage

164. A lady died due to unnatural death within seven years after her marriage. The inquest in this case will be done by

1. Forensic medicine expert
2. Deputy Superintendent of Police
3. Sub-Divisional Magistrate
4. Coroner

165. Cheiloscropy is the study of prints of

1. Foot
2. Fingers

2004

3. Palate
 4. Lips
166. All of the following are the electrocardiographic features of hyperkalemia except
1. Prolonged PR interval
 2. Prolonged QT interval
 3. Sinewave pattern
 4. Loss of P waves
167. A patient with acute inferior wall myocardial infarction has developed shock. Which of the following is the most likely cause of shock
1. Cardiac rupture
 2. Interventricular septal perforation
 3. Papillary muscle rupture
 4. Right ventricular infarction
168. The correct sequence of cell cycle is
1. G₀ – G₁ – S – G₂ – M
 2. G₀ – G₁ – G₂ – S – M
 3. G₀ – M – G₂ – S – G₁
 4. G₀ – G₁ – S – M – G₂
169. Which one of the following cardiac lesions is at highest risk of occurrence of infective endocarditis
1. Atrial septal defect
 2. Mitral valve prolapse without regurgitation
 3. Valvular aortic regurgitation
 4. Mitral stenosis
170. All of the following drugs are used in the management of acute myocardial infarction except
1. Tissue plasminogen activator
 2. Intravenous beta – blockers
 3. Acetylsalicylic acid
 4. Calcium channel blockers
171. The most common cause of sporadic viral encephalitis is
1. Japanese B encephalitis
 2. Herpes simplex encephalitis
 3. Human immunodeficiency virus encephalitis
 4. Rubella encephalitis
172. The only thrombolytic agent approved for the treatment of acute ischemic stroke is
1. Tissue plasminogen activator
 2. Streptokinase
 3. Urokinase
 4. Pro – urokinase
173. All of the following are neurologic channelopathies except
1. Hypokalemia periodic paralysis
 2. Episodic ataxia
 3. Familial hemiplegic migraine
 4. Huntington's disease
174. A 35-year-old male patient presented with history of jaundice for 15 days. The onset was preceded by a prodromal illness. His serum tested positive for HBsAg. A clinical diagnosis of acute hepatitis B was made. What should be the next best confirmatory investigation
1. Anti – HBeAg antibody
 2. HBe antigen
 3. Anti – HBe IgM antibody
 4. HBV DNA by PCR
175. A 20-year-old female presents with history of dyspnea on exertion. On examination, she has wide, fixed split of S₂ with ejection systolic murmur (III/IV) in left second intercostals space. Her EKG shows left axis deviation. The most probable diagnosis is
1. Total anomalous pulmonary venous connection
 2. Tricuspid atresia
 3. Ostium primum atrial septal defect
 4. Tetralogy of Fallot
176. In a patient with chronic congestive cardiac failure, all of the following drugs prolong survival except
1. Metoprolol
 2. Carvedilol
 3. Enalapril
 4. Digoxin
177. All of the following are features of juvenile myoclonic epilepsy, except
1. Myoclonus on awakening
 2. Generalised tonic – clonic seizures
 3. Automatism
 4. Absence seizures
178. All of the following statements about Creutzfeldt – Jakob disease are true, except
1. It is a neurodegenerative disease
 2. It is caused by infectious proteins
 3. Myoclonus is rarely seen
 4. Brain body is specific for diagnosis
179. All the following statements about Wilson's disease are true, except
1. It is an autosomal recessive disorder
 2. Serum ceruloplasmin level is < 20 mg/dl
 3. Urinary copper excretion is < 100 g/day
 4. Zinc acetate is effective as maintenance therapy
180. Which of the following is the most predominant constituent of sulfur granules of actinomycosis is
1. Organisms
 2. Neutrophils and monocytes
 3. Monocytes and lymphocytes
 4. Eosinophils
181. Conjugate vaccines are available for the prevention of invasive disease caused by all of the following bacteria, except
1. Haemophilus influenzae
 2. Streptococcus pneumoniae
 3. Neisseria meningitidis (Group C)

2004

4. *Neisseria meningitidis* (Group B)
182. A clinical specimen was obtained from the wound of a patient diagnosed as Nocardiosis. For the selective isolation of *Nocardia* sp. Which one of the following would be the best method
1. Paraffin bait technique
 2. Castaneda's culture method
 3. Criage's tube method
 4. Hair bait technique
183. Anti-tubercular drug susceptibility can be done by all of the following methods, except
1. Resistance ratio method
 2. Disc diffusion method
 3. Molecular method
 4. Radiometric broth method
184. A neonate develops signs of meningitis at seven days of birth. The presence of which of the following infectious agent in the maternal genital can be the causative agent of this disease
1. *Neisseria gonorrhoeal*
 2. *Chlamydia trachomatis*
 3. *Streptococcus agalactiae*
 4. *Haemophilus ducreyi*
185. Tablets supplied by Govt. of India contain the following amount of iron and folic acid
1. 60 mg elemental iron + 500 g FA
 2. 100 mg elemental iron + 500 g FA
 3. 200 mg elemental iron + 1mg FA
 4. 100 mg elemental iron + 5mg FA
186. All of the following are used for induction of labour except
1. PG F2 tablet
 2. PG E1 tablet
 3. PG E2 gel
 4. Misoprostol
187. All of the following agents are used for emergency contraception except
1. Danazol
 2. Levonorgestrel
 3. Misoprostol
 4. Mifepristone
188. In which of the following conditions the medical treatment of Ectopic Pregnancy is contraindicated
1. Sac size is 3 cm
 2. Blood in Pelvis is 70 ml
 3. Presence of Fetal Heart activity
 4. Previous Ectopic Pregnancy
189. Emergency contraceptives are effective if administered within following period after unprotected coitus
1. 24 hours
 2. 48 hours
 3. 72 hours
 4. 120 hours
190. Minimum effective dose of ethinyl estradiol in combined oral pills is
1. 20 gm
 2. 35 gm
 3. 50 gm
 4. 75 gm
191. From which of the following layers the regeneration of endometrium takes place
1. Zona basalis
 2. Zona pellucidum
 3. Zona compacta
 4. Zona spongiosa
192. All of the following pelvic structures support the vagina, except
1. Perineal body
 2. Pelvic diaphragm
 3. Levator ani muscle
 4. Infundibulopelvic ligament
193. Nevirapine is a
1. Protease inhibitor
 2. Nucleoside transcriptase inhibitor
 3. Non-nucleoside reverse transcriptase inhibitor
 4. Fusion inhibitor
194. Which one of the following substances is the most potent androgen
1. Dihydroepiandrosterone
 2. Dihydrotestosterone
 3. Androstendione
 4. Testosterone
195. Women receiving Tamoxifen should be periodically screened by
1. Mammography
 2. Pap smear
 3. CA-125 level
 4. Endometrial sampling
196. Conservative management is contraindicated in a case of placenta praevia under the following situations except
1. Evidence of fetal distress
 2. Fetal Malformations
 3. Mother in a haemodynamic unstable condition
 4. Women in labour
197. A case of gestational trophoblastic neoplasia is detected to have lung Metastasis. She should be staged as
1. Stage-I
 2. Stage-II
 3. Stage-III
 4. Stage-IV

;

2004

198. All of the following are the indications for Myomectomy in a case of fibroid uterus, except

1. Associated Infertility
2. Recurrent pregnancy loss
3. Pressure symptoms
4. Red degeneration

199. Which one of the following is the best drug of choice for treatment of bacterial vaginosis during pregnancy

1. Clindamycin
2. Metronidazole
3. Erythromycin
4. Rovamycin

200. A 33-year-old man presented with a slowly progressive swelling in the middle 1/3rd of his right tibia. X-rays examination revealed multiple sharply demarcated radiolucent lesions separated by areas of dense and sclerotic bone. Microscopic examination of a biopsy specimen revealed island of epithelial cells in a fibrous stroma. Which of the following is the most probable diagnosis

1. Adamantinoma
2. Osteofibrous dysplasia
3. Osteosarcoma
4. Fibrous cortical defect